

## Mitigating Some Guesswork In Treating Neuropathic Pain

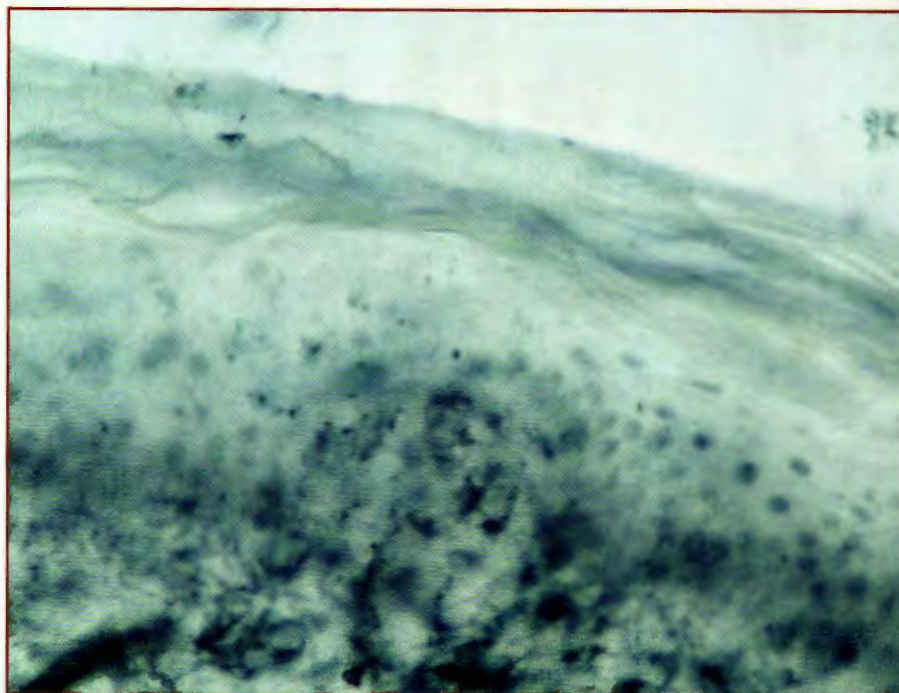
**N**europathies take many forms depending on anatomic location. A mononeuropathy affects a single spinal or peripheral nerve with the cause likely to be a distinct anatomic lesion (such as lesions due to disc disease or tarsal tunnel syndrome). Systemic neuropathies often cause symmetrical issues in the limbs. Common causes are diabetes, alcohol, chemotherapy, etc.

Accordingly, let us take a closer look at the differentiation and treatment of distal neuropathies. Peripheral neuropathies come from damage or diseases affecting nerves that produce symptoms related to dysfunction in the nerve itself. This is in contrast to nociceptive pain, in which the nerve's performance is normal.

Consider the following patient. A 76-year-old female presents with diabetes and a HgbA1c of 7.6. The patient was in a severe car crash 15 years ago and has had low back pain since. She had breast cancer five years ago and had chemotherapy. The patient describes the pain as an "aching, burning pain" that makes it hard to sleep. She notes there is some reduction of the pain with walking. The patient reports seeing three other doctors who could not help address her pain.

The most crucial elements of the history are the symptoms and location of the neuropathy. See "A Guide To Signs And Symptoms Of The Onset Of Neuropathy" on page 19. It is important to document positive and negative findings because improvement in any of these can be valuable in tracking the progress of your patient.

Perhaps more crucial to the diagnosis, in our opinion, is the location of neuropathy. If it is peripheral, circumferential and roughly symmetric, one can be reasonably sure there is a systemic cause (such as diabetes or a toxin). The causes of asymmetric neuropathies, which are prevalent in



A 65-year-old female presented with diabetic peripheral neuropathy. She received 16 combined electrochemical treatments (CETs) over the course of three and a half months, but stopped treatment to have a total knee replacement. At that time, she had 70 percent improvement in symptoms including balance. Her pain returned but she had an additional four combined electrochemical treatments with improvement. The above image is a pre-CET epidermal nerve biopsy.

the lower extremities, are typically associated with isolated lesions. Causes include disc disease, trauma and entrapments.

A proper history is crucial to find a cause. Did the patient work in an environment where she would have been exposed to heavy metals? Was she exposed to Lyme disease? One must know the social history and nutritional history to look for vitamin deficiencies of B6, B12, folate, vitamin D, etc.

Two useful tools are a peripheral arterial disease questionnaire and the neuropathy function index. These are easy surveys that will help in triaging, treatment and measuring a patient's progress.

How does one differentiate among the various causes of peripheral neuropathy?

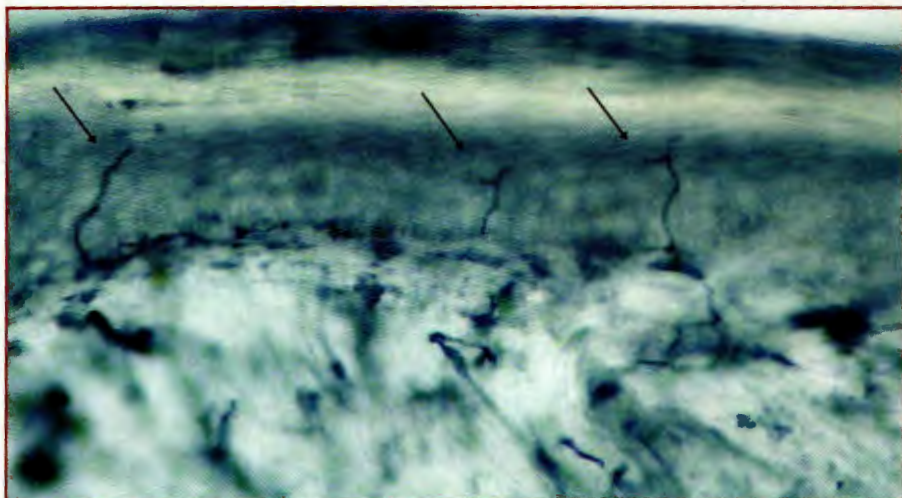
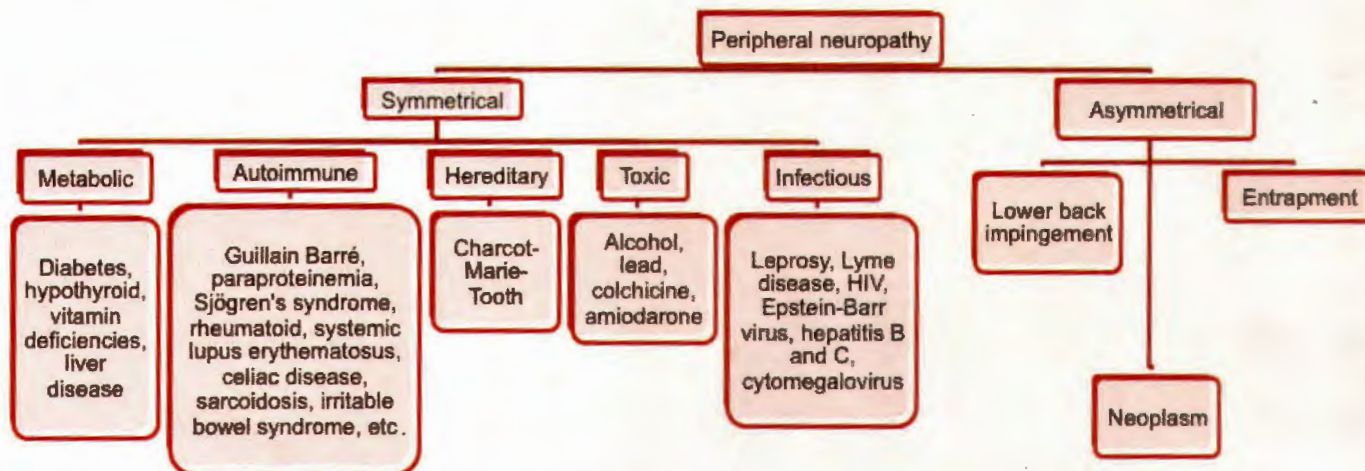
Developing an algorithmic approach can save time and medical resources. Ordering tests to rule out all possible causes could be very expensive. Clinical judgment can help narrow the list of possibilities.

### Conducting An Effective Physical Examination

The physical examination should include a limited back exam and full lower extremity exam. As part of the foot exam, we utilize several objective tests. Standard tests include the Semmes Weinstein monofilament test, the Rydel-Seiffer eight-point vibration scale, sensory testing with a sharp and a dull instrument, temperature testing, Tinel's sign, two-point discrimination, and pressure specified sen-



## An Algorithm To Determine The Causes Of Neuropathy



Three months later, the 65-year-old patient had a second epidermal nerve fiber density biopsy. The above image shows findings from the post-CET epidermal nerve biopsy. The patient reported a 75 percent reduction in sensory symptoms (pain, numbness and dysesthesias) and a symptom score of 2 to 3/10 on the visual analogue scale. There were improvements in balance, sleep, attitude and quality of life. She has 90 percent improvement in function to date. Epidermal nerve regrowth was present in the foot (0 to 3.4 nerve fibers/mm), calf and thigh (an increase of 1.6 nerve fibers/mm).

sory testing. While exhaustive and time-consuming, these tests will serve to map the location (e.g. proximal spread) and quantitate the nature and severity of the neuropathy. These tests are quite useful in tracking a patient's progress.

The loss of vibration and/or light touch sensation around the entire limb may mean undiagnosed diabetes or idiopathic peripheral neuropathy. Often, these findings represent a decrease in the function of the small nerve fibers. If these findings are confined to a single dermatome, one

should suspect a lumbar radiculopathy, a more proximal entrapment syndrome or another type of neuropathy.

### What Diagnostic Testing Can Reveal About The Cause Of Neuropathy

Blood tests can be useful in finding a specific cause for neuropathy. Hemoglobin A1c reflects the average blood sugar and can track a patient's adherence over three months. To maximize the treatment of neuropathy, an HgbA1c of 7.0 or below

should be the goal. The GlycoMark test (GlycoMark, Inc.) is a blood test that reports a two-week average measure of the maximum blood glucose.

Nutritional screening is important because the B vitamins and vitamin D are often deficient. Clinicians should check blood levels to minimize potential toxicity if patients are taking high doses of fat-soluble vitamins.

Comprehensive neuropathy testing includes: lead, mercury, arsenic levels, vitamin B6 level, B12 levels, a Lyme titer, RPR (rapid plasma reagin) syphilis test and complete blood cell count with differential to evaluate for possible anemia. Comprehensive testing should be individualized to each case and be the decision of each practitioner. Bear in mind that testing can be very expensive and may not influence treatment.

The "standard" in objective nerve testing remains nerve conduction/electromyography (EMG), especially if one suspects nerve entrapment. We believe there is little evidence for ordering these tests in diagnosing systemic neuropathies. Often, the report states "diffuse peripheral polyneuropathy with both axonal and demyelinating features," which one would already know.

The A-delta nerve conduction study, a relatively new test for small fiber neuropathy, has been in use for over 10 years. We believe this test is more useful to evaluate efficacy of the neuropathy treatment



## A Guide To Signs And Symptoms Of The Onset Of Neuropathy

- 1) Gradual onset of numbness and tingling in feet, which may spread proximally
- 2) Sharp, shooting or burning pain
- 3) Allodynia
- 4) Imbalance
- 5) Muscle weakness or paralysis if motor nerves are affected

If autonomic nerves are affected, signs and symptoms may include:

- Heat intolerance
- Changes in blood pressure, causing dizziness or lightheadedness
- Dry skin and feet that do not sweat
- Skin atrophy

but it is not widely available at this time.

The epidermal nerve fiber density test is a new gold standard that has emerged for the diagnosis of peripheral neuropathy.<sup>1</sup> Physicians and labs advocate using one to three biopsy sites with a 2 mm punch biopsy. Common testing sites are: the proximal thigh (10 cm from the hip), the distal thigh (10 cm from the knee), 10 cm above the lateral malleolus and on the lateral midfoot. Systemic neuropathies often show a decrease in small nerve fiber density and this simple test can quantify improvement in neuropathy.

## What You Should Know About Diabetic Neuropathy Treatments

**Nutritional.** Alpha lipoic acid, vitamin B complexes and vitamin D supplementation have shown improvement in neuropathic symptoms in numerous studies. According to a *Cochrane Review* in 2008, most studies did not show significant improvement in peripheral neuropathy using vitamin B only.<sup>2</sup> Using epidermal nerve biopsy, Jacobs found that a combination of L-methylfolate, methylcobalamin and pyridoxal 5'-phosphate (Metanx, Pamlab) decreased neuropathic symptoms and showed an increase in epidermal nerve fiber density.<sup>3</sup>

**Pharmacological.** Gabapentin (Neurontin, Pfizer) received FDA approval in 1993 and has been the subject of multiple double-blind studies. According to Moore and colleagues, the number needed to treat ranged between 4.8 to 8.7.<sup>4</sup> Sixty-six percent of patients experienced adverse events and 12 percent withdrew because of adverse events. Serious events were no more common in the treatment group

than placebo (4 percent).

Pregabalin (Lyrica, Pfizer) received FDA approval in 2004. Finnerup and coworkers state that the number needed to treat ranged from 3.3 to 4.7.<sup>5</sup> In studies, 22 to 38 percent of patients taking pregabalin experienced adverse events with rare withdrawal from therapy due to side effects.<sup>5</sup>

**Compound creams.** An enticing treatment option to prevent systemic side effects, compound creams have shown mixed results for us. To our knowledge, no high-powered studies have demonstrated efficacy with compound creams. Most compounding pharmacies use their own specific combinations, which makes it difficult to determine which compounds are most effective and in determining the number needed to treat.

## Current Insights On An Emerging Treatment

Combined electrochemical treatment (CET) has shown promising results in several small studies.<sup>6-9</sup> We have covered our current treatment protocol in other previous published papers.<sup>7,8</sup> These studies have shown up to 80 percent of patients experiencing significant relief from their neuropathic symptoms.<sup>6-8</sup> Before and after epidermal nerve biopsies have proven that combined electrochemical treatment increases the epidermal nerve fiber density. The combined electrochemical treatment shows very impressive results in comparison to traditional therapies for systemic neuropathies.

Larger studies are needed to improve the acceptance of combined electrochemical treatment by third-party payers. As long-term patient success continues to

be documented at substantially reduced overall costs for neuropathy treatment, the third-party payers will be more forthcoming with appropriate reimbursement. ■

*Dr. Cernak is affiliated with Weil Foot & Ankle Institute in Kenosha, Wis.*

*Dr. Larsen is affiliated with Weil Foot & Ankle Institute in Kenosha, Wis.*

*Dr. Odell is affiliated with Neuropathy & Pain Centers of America in Las Vegas.*

## References

1. Saperstein DS, Levine TD. Diagnosing small fiber neuropathy through the use of skin biopsy. *Practical Neurology*. 2009; 8(1):37-40
2. Ang CD, Alviar MJM, Dans AL, Bautista-Velez GGP, Villaruz-Sulit MVC, Tan JJ, Co HU, Bautista MRM, Roxas AA. Vitamin B for treating peripheral neuropathy. *Cochrane Database Syst Rev*. 2008; 16(3):CD004573.
3. Jacobs AM, Cheng D. Management of diabetic small-fiber neuropathy with combination L-methylfolate, methylcobalamin, and pyridoxal 5'-phosphate. *Rev Neurol Dis*. 2011; 8(1-2):39-47.
4. Moore RA, Wiffen PJ, Derry S, McQuay HJ. Gabapentin for chronic neuropathic pain and fibromyalgia in adults. *Cochrane Database Syst Rev*. 2011 16;(3):CD007938
5. Finnerup NB, Jensen TS. Clinical use of pregabalin in the management of central neuropathic pain. *Neuropsychiatric Disease Treat*. 2007; 3(6):885-891.
6. Odell RH, Sorgnard RE. New device combines electrical currents and local anesthetic for pain management. *Practical Pain Management*. 2011; 11(6):52-68
7. Cernak C, Marriott E, Martini J, Fleischmann J. Electric current and local anesthetic combination successfully treats pain associated with diabetic neuropathy. *Practical Pain Management*. 2012; 12(3):23-36.
8. Cernak C, Odell R, Carney P. Can combined electrochemical treatment have an impact for diabetic peripheral neuropathy? *Podiatry Today*. 2014; 27(7):20-24.
9. Carney PM. Quantum theory treats neuropathy better than pharmacology. *The Pain Practitioner*. 2014: 28-31

*For further reading, see "Can Combined Electrochemical Treatment Have An Impact For Diabetic Peripheral Neuropathy?" in the July 2014 issue of Podiatry Today.*