

An Economical Approach to Ethnic Asian Rhinoplasty

Jonathan Zelken, MD¹ Chun-Shin Chang, MD¹ Shiow-Shuh Chuang, MD¹ Jui-Yung Yang, MD¹
Yen-Chang Hsiao, MD¹

¹Department of Plastic and Reconstructive Surgery, Chang Gung Memorial Hospital, Taiwan, China

Address for correspondence Yen-Chang Hsiao, MD, Chang Gung Memorial Hospital, Plastic and Reconstructive Surgery, F11, No. 213, Wen-Shin Road, Taoyuan, Taiwan (e-mail: b8301063@gmail.com).

Facial Plast Surg 2016;32:95–104.

Abstract

Septal cartilage is deficient in Asians seeking augmentation rhinoplasty. Economized utilization of resources is necessary for durable tip enhancement that complements a dorsal implant. We introduce a modified tongue-in-groove method designed to transmit forces across the dorsum, eliminating the need for robust caudal support and prioritizing nasal lengthening and tip projection. We aim to promote the roundness index parameter and demonstrate the feasibility of a novel method in the context of Asian rhinoplasty. Between 2012 and 2014, a total of 104 Taiwanese patients underwent rhinoplasty with dorsal augmentation and lengthening with a modified tongue-in-groove technique. The concept borrows from methods established by Byrd, Guyuron, and Toriumi but distinguished by exaggerated forward positioning of a septal extension graft. Paired extended spreader grafts obviate the need for a columellar strut. Soft-tissue changes were analyzed with photogrammetry. A new parameter, the roundness index, was measured. Tip projection, dorsal length, nasal height, alar and columellar length increased significantly after 5.5 months of follow-up. Nasal tip angle, roundness, columella-labial angle, and nostril axis inclination decreased. There were no statistically significant differences in the magnitude of change in patients followed for less than and greater than 6 months. The most common complication was new or persistent tip deviation in five cases (5%). This technique was designed for a nasal anatomy typified by deficient septal cartilage. Significant photogrammetric changes were maintained after 6 months. Economized tissue allocation, dorsal septal load sharing, and relative independence from caudal support are key features of this feasible method.

Keywords

- ▶ rhinoplasty
- ▶ spreader graft
- ▶ ethnic Asian rhinoplasty

As worldwide wealth accumulates among ethnic Asians and stigma dissipates, there is an increasing demand for aesthetic surgery that emphasizes enhancement of natural beauty rather than Westernization. Rhinoplasty is increasingly common, second to blepharoplasty in popularity. A new set of aesthetic standards specific to the ethnic Asian nose is emerging.¹ As standards evolve, so do the methods to achieve them; this is demonstrated by a rapidly expanding literature.

Even though significant variation exists, several features characterize the stereotypical Asian nose: thick skin, low bridge, and a blunted and underprojected tip. When these features become disharmonic, tip projection and nasal lengthening can

be achieved using a septal extension graft (SEG) as described by Byrd et al,² or one of many iterations.^{3–12} Although alloplastic^{5,11,13} and allogeneic materials¹² have been used, autologous septal cartilage is widely advocated as the best donor¹⁴ and the authors' preferred medium. Deficiencies in septal cartilage impose a vexing paradox: how does one pay Paul when Peter has little to offer?

The deft plastic surgeon must address the cultural values, high demands, and individual goals of his/her Asian patients. Objectives of rhinoplasty in this demographic include economized allocation of autogenous resources to achieve long-lasting results. We present a modification of the well-established

tongue-in-groove concept.^{2,15-17} This modification is distinguished by forward positioning of a direct-onlay SEG with load transmission more through the dorsum than caudal structures. We intend to demonstrate the feasibility of our modification in the context of Asian rhinoplasty and summarize our experience.

Patients and Methods

Between 2012 and 2014, a total of 104 ethnically Asian patients were treated at Chang Gung Memorial Hospital by a single surgeon for dorsal augmentation and modified tongue-in-groove (M-TAG) lengthening (►Table 1). The average age of patients was 33.8 years (range, 18–64 years). There were 12 men and 92 women. Preoperative and postoperative images included standardized lateral and worm’s-eye views (►Fig. 1).

Primary rhinoplasty was performed in 78 patients (75%). Secondary rhinoplasty was performed in 26 patients (25%) after trauma or previous surgery, with implant exchange in 14 patients. Every operation was performed under general anesthesia. Common complaints were foreshortened nose, underprojected or malrotated tip, hanging columella, and nasal congestion; indications were cosmetic in 96 cases (92%) and cosmetic and functional in 8 cases (8%). Dorsal augmentation was performed in every case. A composite extended polytetrafluoroethylene (ePTFE)-lined silicone implant (Implantech, Ventura, CA) was used in 98 patients, a traditional silicone implant was used in 5 patients, and autologous dermal graft was used in 1 patient. Alar reduction was performed in twelve cases (12%), radix augmentation in three cases (3%), and nasal osteotomies in seven (7%). Alar batten grafting, columellar plumping, tip grafting, and other refinements were performed as indicated. Additional (extranasal) facial procedures were performed in 22 cases (21%) that ranged from injectables to facelift.

Operative Technique

After trimming vibrissae, 2% lidocaine with 1:100,000 epinephrine was tumesced and allowed to take effect. A mid-columellar inverted-V incision was made and the alar cartilages were exposed through a marginal incision. Supraperichondrial dissection along the lower lateral cartilages (LLC) and upper lateral cartilages (ULC) transitioned to a subperiosteal plane at the nasal bone. The LLCs were released from the ULCs at the scroll area and the medial crura were teased apart to expose the septum in the submucoperichondrial plane. As much septal cartilage as possible was harvested, taking special care to preserve a 10-mm-wide L-shaped caudal–dorsal strut. The dorsal septum was separated from the ULCs to create a pocket for spreader graft interposition.

In most cases, cartilage was allocated to one SEG, two extended spreader grafts (ESGs), a tip graft, and a shield graft (►Fig. 2A–C). SEG position was tailored to cartilage supply, deficiencies, and aesthetic goals. The dimensions, shape, and position of components reflected patient goals and traits. Septal cartilage was reserved for tip projection; for example, in the case of a retrusive columella and

Table 1 Patient demographics

Indications	Demography			Other procedural details					Outcomes					
	Rhinoplasty	n	Cosmetic only	M	F	Age	Follow-up (mo)	Alar reduction	Cartilage used	Dorsal augmentation	Radix augmented	Osteotomy	Complications	Revision surgery
Primary	78 (75%)	90%	10	68	33.8	4.7		8 (10%)	S 78 (100%) C 72 (92%)	Ch 75 (96%) Si 3 (4%)	3 (4%)	6 (8%)	Minor deviation 2 (3%) Major deviation 2 (3%)	2 (3%)
Secondary	26 (25%)	100%	2	24	41.2	8		4 (15%)	S 26 (100%) C 24 (92%)	Ch 23 (88%) Si 2 (8%) DF 1 (4%)	0	1 (4%)	Minor deviation 1 (4%)	1 (4%)
Total	104	92%	12	92	33.8	5.5		12 (12%)	S 104 (100%) C 96 (92%)	Ch 98 (94%) Si 5 (5%) DF 1 (1%)	3 (3%)	7 (7%)	Minor deviation 5 (5%)	3 (3%)

Abbreviations: C, conchal; Ch, chimeric implant; DF, dermal-fat graft; S, septal; Si, silicone implant.

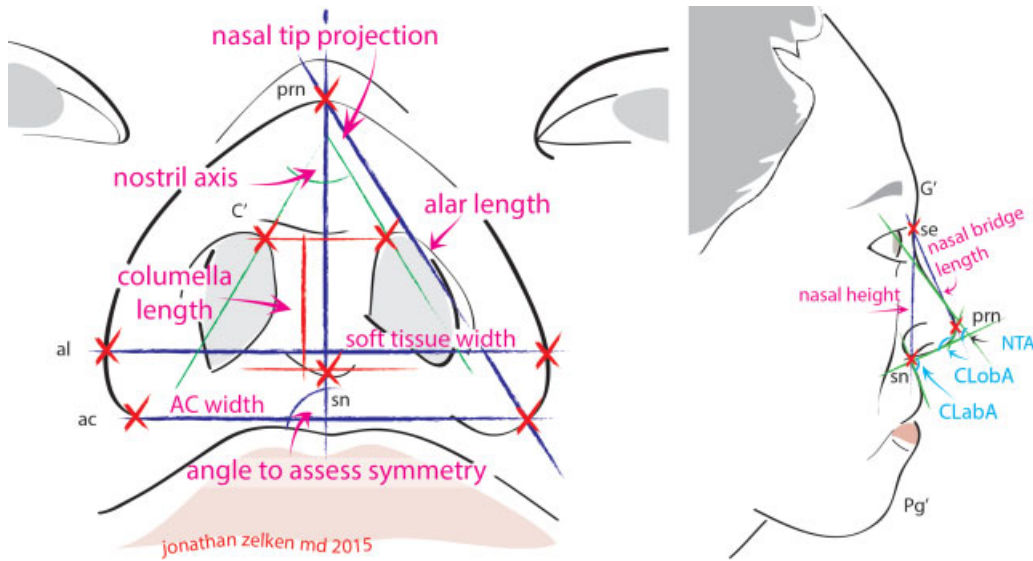


Fig. 1 Worm's eye (left) and lateral (right) views were studied preoperatively and postoperatively. Landmarks included the sellion (se), subnasale (sn), glabella (G'), pogonion (Pg'), pronasale (prn), alar curvature point (ac), alare (al), intercanthal distance (ICD), and columella (c'). Measurements were standardized using glabella–pogonion distance (lateral view) and ICD (worm's eye). NTA, nasal tip angle; ClobA, columella-lobule angle; ClabA, columella-labial angle.

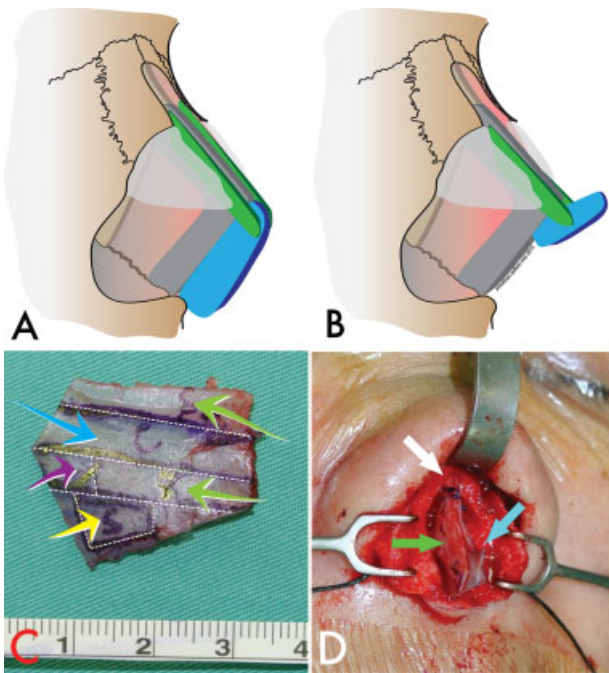


Fig. 2 Comparison of traditional (Toriumi-style) tongue-and-groove method (A) and the economical modified method (B). Both feature paired extended spreader grafts (green) and a septal extension graft (blue). Our modified technique relies on cantilever-type load transmission across the spreader grafts and the dorsal septum. Additional support is derived from direct abutment and load transmission through the caudal septum. A partial-length SEG is easy to modulate, does not influence columella position or nasolabial angle, and expends less resources. (C) Septal cartilage (white dashed line) resource allocation to extended spreader (green arrows) septal extension (blue arrow), shield (yellow arrow), and cap (purple arrow) grafts used in Case 2. (D). Intraoperative view showing septal (white arrow) extension (green arrow) and septal extension graft (green arrow) construct prior to added tip support and refinement grafting.

underprojected tip, forward SEG allocation was favored and other (nonseptal cartilage) resources were used for columellar augmentation.

Depending on donor supply and goals, 20 to 30 mm × 4 to 5 mm ESGs were positioned between the ULCs and septum (→ Fig. 2D). Tip-defining points of the LLCs were identified and the LLCs were sutured to the SEG complex in optimal position. The SEG was positioned like a jackknife blade to obtain the desired shape. Any surplus material was used for tip grafting and columellar plumping. In most cases, there was little to no excess and conchal cartilage was used instead. Conchal cartilage was used as a cap graft or shield graft.

After establishing tip position, attention was turned to dorsal augmentation. The mucosa and skin were closed in one layer. Quilting transfixion sutures secured the mucoperichondrial flaps to prevent hematoma. Skin was closed with 4-0 chromic suture; tape and splints were applied in every case.

Photographic Evaluation

Pre- and postoperative photographs were analyzed with previously described photogrammetric methodology.¹⁸ Landmarks used in the worm's-eye view were the pronasale (prn), subnasale (sn), alare (al), alare curvature point (ac), and columellar apex (c'). To standardize worm's-eye measurements, the intercanthal distance (ICD) was measured as a standard to adjust for changes in scale. For example, soft-tissue width/ICD generated a soft-tissue width index (SWI). We also documented the ac-ac width index (ACWI), alar length index, and columellar length index (→ Table 2, → Fig. 1). The sellion (se), sn, and prn were used in the lateral view. The tip projection index (TPI), base length index (BLI), and nasal height index (NHI) reflected the pogonion–glabella distance as a standard. Symmetry was determined by the deviation from perpendicular of the ac-ac and sn-prn axes. In addition, columella-labial angle (CLabA), columella-lobule angle, and nasal tip angle (NTA) were measured using the

Table 2 Aesthetic parameters

Parameter	Abbreviation	Formula	View
Nasal profile			
Nasal height index	NHI	$(se-sn)/(G'-Pg')$	Lateral
Tip projection index	TPI	$(prn-sn)/(G'-Pg')$	Lateral
Bridge length index	BLI	$(se-prn)/(G'-Pg')$	Lateral
Tip position			
Roundness index	RI	Best-fit circle diameter/(prn-sn)	Lateral
Nasal tip angle (of Joseph)	NTA	Angle between dorsal and columellar plane	Lateral
Divergence from symmetry	-	90 degrees (angle between ac-ac and sn-prn plane)	Worm's eye
Columella			
Columella-labial angle	CLabA	Angle between labial and columellar plane	Lateral
Columella-lobule angle	CLobA	Angle between columellar and nasal lobular plane	Lateral
Nasal base			
Soft-tissue width index	SWI	$(al-al)/ICD$	Worm's eye
ac-ac width index	ACWI	$(ac-ac)/ICD$	Worm's eye
Columella length index	CLI	$(c'-sn)/ICD$	Worm's eye
Alar length index	ALI	$(prn-ac)/ICD$	Worm's eye
Nostril axis inclination	-	Angle between nostril axes	Worm's eye

Abbreviations: ac, alar curvature point; al, alare; c', highest point on columella; G', glabella; ICD, intercanthal distance; Pg', pogonion; prn, pronasale; se, sellion; sn, subnasale.

Photoshop CS6 measure tool (Adobe Systems, Inc., San Jose, CA). The NTA was determined by estimating a subjective line of best fit along the dorsum and columella as described by Joseph.¹⁹ Pre- and postoperative data were compared.

Roundness Index

We measured the roundness of each nose using a novel parameter, the *roundness index* (RI). Using the same Adobe software, the largest circle that could fit into the nasal profile was measured that abutted the *prn* (→ Fig. 3). Using the same unit of measure, nasal tip projection was measured. The ratio of diameter-to-tip projection was the RI.

Outcomes and Comparisons

Pre- and postoperative photogrammetric parameters were compared using the two-tailed Student *t*-test. All data were evaluated using SPSS software (Version 17.0; SPSS, Inc., Chicago, IL). Significance was established with values of $p < 0.05$. To get a better sense of result of durability, relative changes in parameters before and after surgery were evaluated in patients followed for less than 6 months, and for 6 or more months. Chart data were reviewed to assess for complications, techniques, and revisions.

Results

Patients were followed up for 5.5 months (range, 1 month–3 years) (→ Table 3). Thirty-two patients (31%) were followed up for longer than 6 months. No patient was lost to follow-up. In all patients, nasal BLI increased from $31.7 \pm 3\%$ to $36.8 \pm 3\%$ ($p < 0.0001$). NHI increased from $38.8 \pm 3\%$ to $44.0 \pm 3\%$

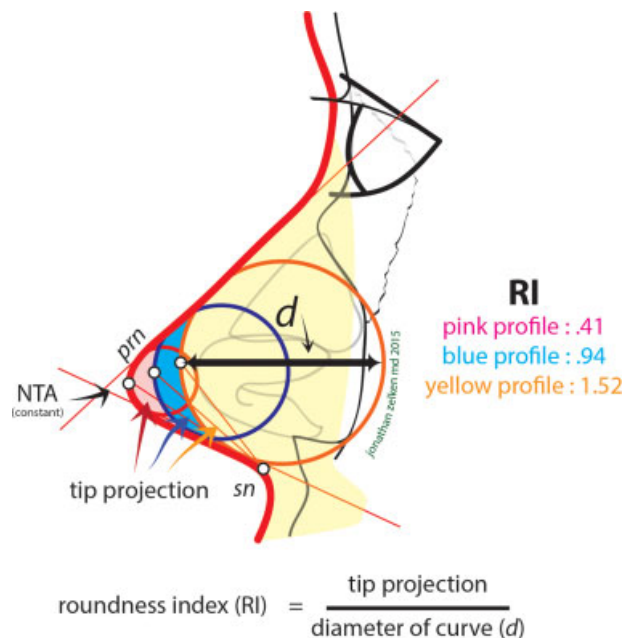


Fig. 3 Roundness index. The largest circle abutting the *prn* within the boundaries of the nasal profile is drawn and the diameter is measured; this is the numerator. Nasal projection, as determined by *prn-sn* distance, is the denominator. Elongation of the foreshortened round nose has less of an effect on nasal tip angle as roundness index, as seen by the varying indices and an unchanged tip angle. *prn*, pronasale; *sn*, subnasale; NTA, nasal tip angle.

($p < 0.0001$). CLabA did not change significantly from 93.2 ± 11.6 degrees to 91.5 ± 10.9 degrees overall, but for 12 patients (12%) who started with an obtuse angle (CLabA > 110 degrees), CLabA decreased from 112.3 ± 1.8 degrees to

Table 3 Aesthetic results by photogrammetric evaluation

	Preoperative value	Postoperative value	<i>p</i> ^a
Nasal profile			
NHI	38.8 ± 3%	44 ± 3.3%	<0.0001 ^a
TPI	14.9 ± 1.5%	16.4 ± 1.5%	<0.0001 ^a
BLI	31.7 ± 3.3%	36.8 ± 3.5%	<0.0001 ^a
Tip position			
RI	1.2 ± 0.16	1.0 ± 0.13	<0.0001 ^a
NTA	81.6 ± 8.2 degrees	79.2 ± 6.6 degrees	<0.05 ^a
Divergence from symmetry	2.2 ± 2 degrees	1.7 ± 1.3 degrees	<0.05 ^a
Columella			
CLabA	93.2 ± 11.6 degrees	91.5 ± 10.9 degrees	NS
CLobA	145.7 ± 8.3 degrees	147.7 ± 7.2 degrees	NS
Nasal base			
SWI	117.5 ± 12.3%	118.5 ± 13.7%	NS
ACWI	107.4 ± 13.6%	110.8 ± 14.2%	NS
CLI	25.6 ± 5%	30.3 ± 6%	<0.0001 ^a
ALI	90.1 ± 11.2%	97.2 ± 12.1%	<0.0001 ^a
Nostril axis	89 ± 11.9 degrees	81.8 ± 12.9 degrees	<0.0001 ^a

Abbreviations: ACWI, ac-ac width index; ALI, alar length index; BLI, bridge length index; CLabA, columella-labial angle; CLI, columellar length index; CLobA, columella-lobule angle; NHI, nasal height index; NS, not significant; NTA, nasal tip angle; RI, roundness index; SWI, soft-tissue width index; TPI, tip projection index.

^a*p* < 0.05.

101.3 ± 11.6 degrees (*p* < 0.01); in 41 patients (39%) with an acute angle (CLabA < 90 degrees), CLabA increased from 81.6 ± 8.2 degrees to 93.3 ± 9.6 degrees (*p* < 0.0001). Nasal TPI increased from 14.9% ± 1.5% to 16.4% ± 1.4% (*p* < 0.0001). NTA decreased somewhat from 81.6 ± 8.2 degrees to 79.2 ± 6.6 degrees (*p* < 0.05). RI decreased 17% from 1.2 ± 0.16 to 1.0 ± 0.13 (*p* < 0.0001). The SWI and ACWI did not change after surgery. The nostril axis decreased from 89 ± 11.9 degrees to 81.8 ± 12.9 degrees (*p* < 0.0001).

Nasal tip deviation decreased from 2.2 ± 2 degrees to 1.7 ± 1.3 degrees (*p* < 0.01). In 10 patients with preoperative deviation exceeding 5 degrees, deviation decreased from 7.0 ± 2.2 degrees to 2.5 ± 2.0 degrees (*p* < 0.0005). The most common complication was new or persistent tip deviation; this occurred in five patients (5%) and required revision tip medialization in three cases. Four of those cases were after primary rhinoplasty; all three revisions followed primary rhinoplasty. Minor complications included a subjective sense of stiffness, tip redness, and widened scars. Implant exposure, hematoma, and inadequate correction were not reported.

Durability

Pre- to postoperative change was compared in patients followed up for less than and greater than 6 months (► **Table 4**). There was no significant difference in the degree of change of any parameter for both follow-up groups. Change in ACWI was greater in patients followed up for ≥6 months (+6.3%) than those followed up for less than 6 months (+2.1%); however,

this did not reach statistical significance (*p* = 0.06). Similarly, the reduction in nostril axis inclination was less in patients followed up for 6 or more months (−4.5 degrees) than those followed up for less than 6 months (−8.3 degrees); again, this did not reach statistical significance (*p* = 0.06).

Case Reports

Case 1

A 21-year-old woman underwent primary cosmetic rhinoplasty for a foreshortened, upturned nose. In addition to blepharoplasty, the M-TAG technique was used to lengthen the nose, and derotate and project the nasal tip (► **Fig. 4**). Septal and conchal cartilages were used for tip refinement, and a chimeric dorsal prosthesis was used. By 2 months, her profile improved significantly; increased NHI, BLI, and TPI reflected this. In this case, NTA was reduced by 25 degrees and RI decreased by 17%.

Case 2

A 25-year-old woman underwent primary cosmetic rhinoplasty for a round, foreshortened nose. Septal and conchal cartilages were used (► **Fig. 2C**) in addition to a chimeric dorsal implant. By 7 months, an interval change in photogrammetric measurements reflected prolongation of the nasal dorsum and improved projection. However, improvement in the tip roundness was less drastic (► **Fig. 5**). The NTA decreased by 1.5 degrees. The modest RI decrease of 1% was consistent with the relatively unchanged round tip.

Table 4 Durability of results in patients followed up for less than 6 months and greater than or equal to 6 months

Follow-up time	<6 mo	≥6 mo	Trend
<i>n</i>	72	32	
Nasal profile			
NHI	+5.3%	+4.8%	Stable ($p = 0.42$)
TPI	+1.5%	+1.4%	Stable ($p = 0.87$)
BLI	+5.1%	+5.1%	Stable ($p = 0.97$)
Tip position			
RI	-0.22	-0.19	Stable ($p = 0.36$)
NTA	-1.9 degrees	-3.6 degrees	Stable ($p = 0.23$)
Asymmetry	-0.4 degree	-0.9 degree	Stable ($p = 0.31$)
Columella			
CLabA	-1.4 degrees	-2.6 degrees	Stable ($p = 0.59$)
ClobA	+2.2 degrees	+1.4 degrees	Stable ($p = 0.70$)
Nasal base			
SWI	+0.2%	+0.3%	Stable ($p = 0.18$)
ACWI	+2.1%	+6.3%	Stable ($p = 0.06$)
CLI	+4.1%	+5.2%	Stable ($p = 0.25$)
ALI	+6.5%	+8.5%	Stable ($p = 0.28$)
Nostril axis	-8.3 degrees	-4.5 degrees	Stable ($p = 0.06$)

Abbreviations: ACWI, ac-ac width index; ALI, alar length index; BLI, bridge length index; CLabA, columella-labial angle; CLI, columellar length index; ClobA, columella-lobule angle; NHI, nasal height index; NTA, nasal tip angle; RI, roundness index; SWI, soft tissue width index; TPI, tip projection index.

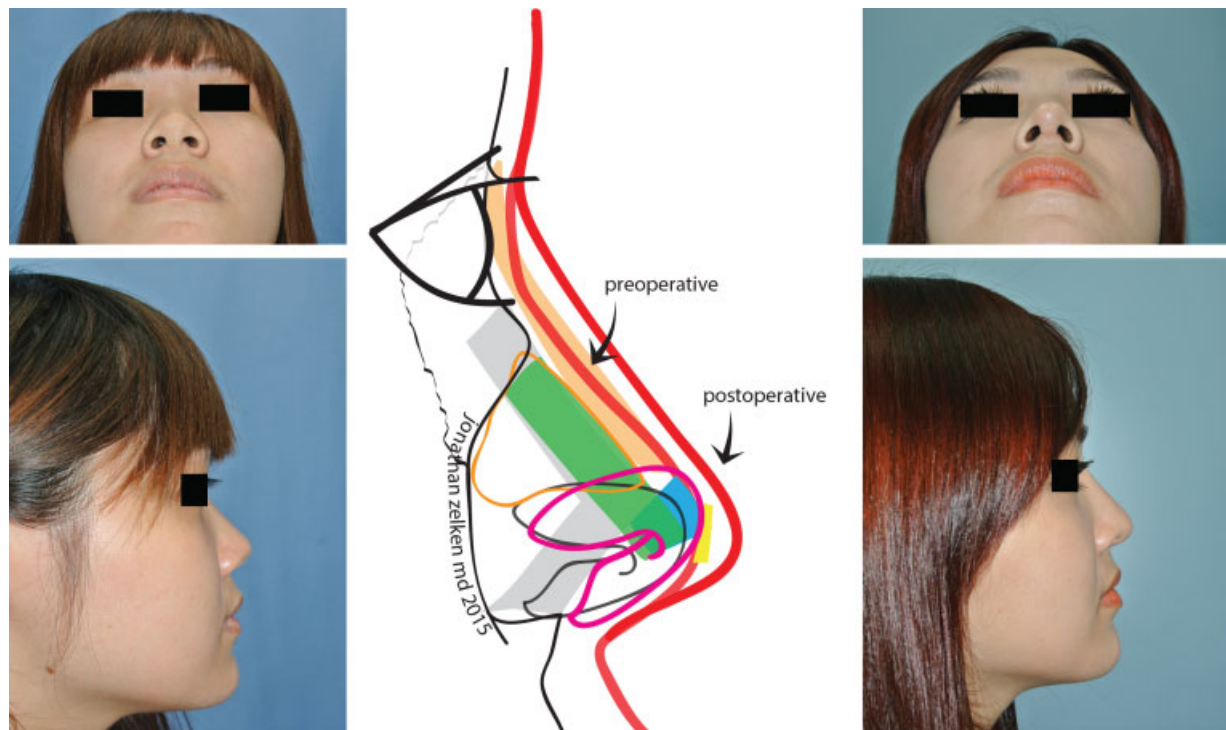


Fig. 4 Case 1. Preoperative appearance (left) of a 21-year-old woman reveals foreshortened, upturned nose without excessive roundness of the tip ($RI = 1.1$) and an oblique tip angle. ESGs (green, center) were used to sandwich the SEG (blue) in addition to tip graft (yellow) and repositioned of the LLCs (pink). A dorsal onlay graft (orange) was used. The two red lines represent the preoperative and postoperative (right) profiles at 2 months. Postoperatively, the roundness index decreased to 0.9 and the NTA decreased by 25 degrees.

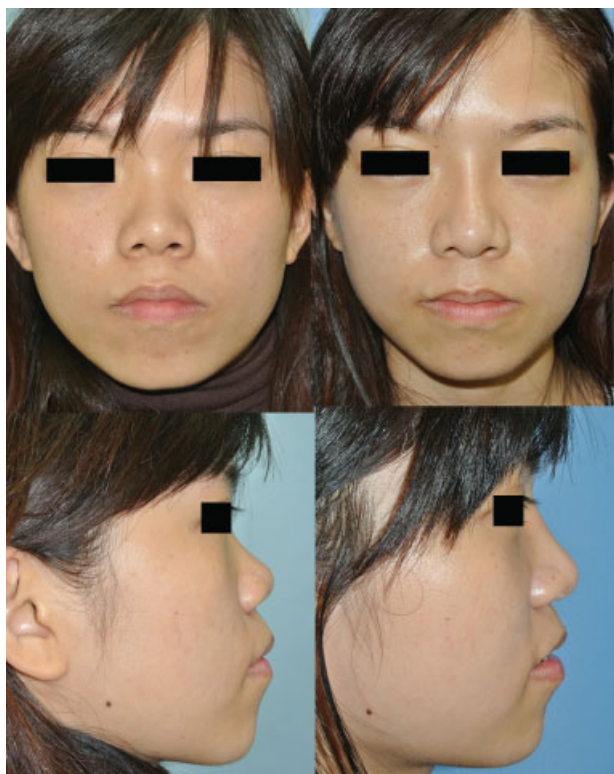

Fig. 5 Case 2. Preoperative (*left*) and 4-month postoperative views (*right*) of a 25-year-old woman treated for a round, upturned nose and low radix. Note the improved appearance from derotation of the entire nasal profile; the shape of the tip and tip angle did not markedly change. This was reflected by increased nasal height and 27-degree reduction in the columella-labial angle despite relatively unchanged RI and NTA measurements.

Case 3

A 19-year-old woman underwent primary cosmetic rhinoplasty for a bulbous and underprojected tip. Septal and conchal cartilage was used to refine the tip and a chimeric implant was used for dorsal augmentation. Nine months later, photogrammetric parameters reflected increased nasal height and bridge length. However, a modest NTA decrease of <10 degrees did not reflect the clinical improvement in tip shape. However, RI decreased by 24%; this was a better reflection of the refinement in tip shape observed on the lateral view (\rightarrow Fig. 6).

Case 4

A 54-year-old woman underwent secondary rhinoplasty for nasal foreshortening with an upturned tip. A previous attempt at lengthening and projection using conchal cartilage and support sutures projected the tip but did not lengthen the nose, resulting in a “pig-nose” deformity. A construct based on septal cartilage and the contralateral conchal cartilage was used to lengthen the nose and derotate the tip. By 3 months, the appearance improved significantly. Tip projection *decreased*, but nasal height and bridge length increased by 18 and 23%, respectively. CLabA decreased by 20 degrees. The NTA did not change. RI decreased by 10% from 1.07 to 0.96 (\rightarrow Fig. 7).

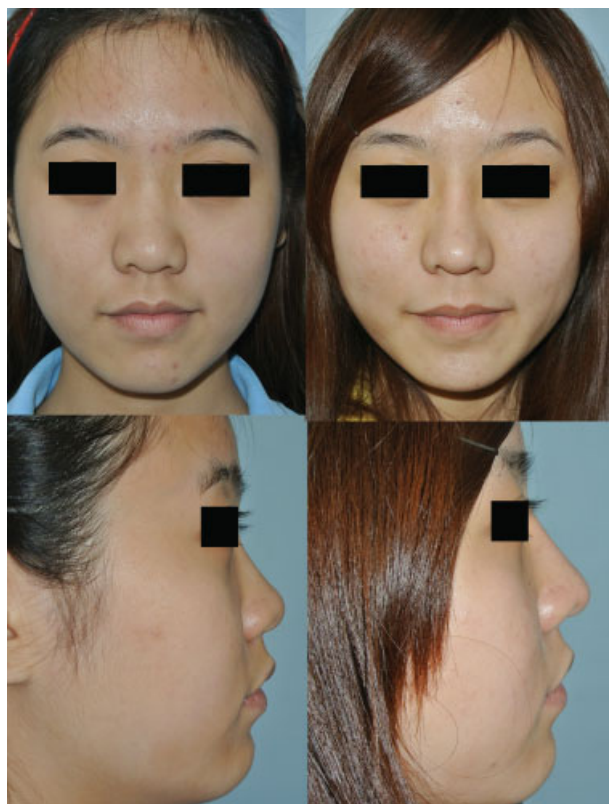

Fig. 6 Case 3. Preoperative (*left*) and 9-month postoperative views (*right*) of a 19-year-old woman treated for round, foreshortened tip. Improvement in round and foreshortened noses such as this is better reflected by change in roundness index (0.4 decrease, 25% reduction) than tip angle (10-degree decrease).

Discussion

Ethnic Asian rhinoplasty is challenging because it is typically augmentative in nature and well-described anatomic and cultural distinctive nuances must be addressed.²⁰ A finite and thick skin envelope and fibrofatty tip limit dorsal augmentation, lengthening, tip projection, and refinement. Temptations to close skin tightly or defat the tip may perpetuate implant exposure and visibility in the short and long term.^{21,22} The choice of alloplastic^{5,11,13} versus autologous tissue in tip modulation and nasal lengthening is surgeon dependent; we prefer autologous tissue for its engraftment potential and lesser extrusion and infection risks. Unfortunately, scarce resources challenge patient and surgeon goals in this context.

The senior author modified preexisting techniques to address the paradoxes of Asian rhinoplasty, favoring forward positioning of the SEG and obtaining stability through the nasal dorsum. By offloading the caudal septum, an area prone to buckling,³ there is no need for caudal reinforcement with a columellar strut or full-length SEG. This allows maximal anterior positioning of the SEG and eliminates vertical columellar augmentation when there is no need for it. When there is need for columellar augmentation, other less structurally significant resources should be used instead. The symmetric

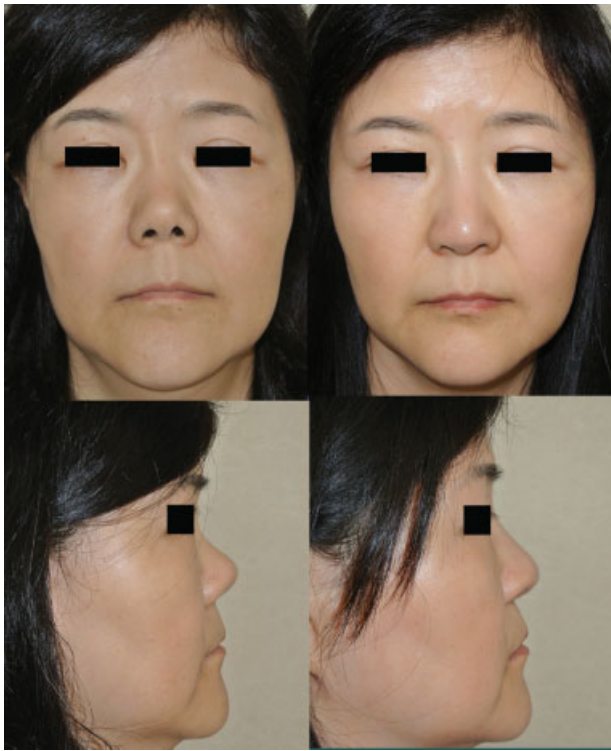

Fig. 7 Case 4. Preoperative (*left*) and 3-month postoperative views (*right*) of a 54-year-old woman treated for an over-projected, over-rotated tip secondary to inadequate prior rhinoplasty. Excellent secondary results can be achieved if the septum has not been used. In this case, change in the nasal tip is better reflected by a 10% decrease in RI and 20-degree decrease in CLabA than the NTA, which did not change.

three-piece construct is conducive to stability and symmetry. Two smaller spreader grafts are expected to confer similar strength as a single, larger graft; this is especially important with the constraints of reduced septal dimensions.

The SEG is positioned end to end with the caudal septum and should not compromise airway patency. Unlike a columellar strut or full-length SEG, the modified SEG can be easily manipulated in three dimensions; a conventional SEG ultimately follows the course of the caudal septum and may be prone to cephalic overrotation. A limited cartilage supply makes it a challenge to obtain projection, support, and nasal lengthening using a single graft.²³ The aforementioned modified technique is designed to accomplish all three goals.

The authors question the importance and significance of the NTA in Asian rhinoplasty. Although postoperative values (79.2 degrees) were consistent with Western norms,^{19,24} we noticed that a true tip angle was difficult to measure in many cases. NTA reduction was significant, but it was a small decrease that did not adequately reflect cosmetic improvement. This disparity may be explained by the round shape of the ethnic Asian nose. A curved profile fills a fraction of a triangle bounded by the dorsal nasal and columellar planes. Elongation of the dorsum (BLI) and increased tip projection decrease roundness more so than reducing the NTA; the RI may better reflect the physical changes we observed. Tip *sharpening* may also confer a masculinizing effect in men (→**Fig. 8**).

The RI reflects changes in dorsal length, tip rotation, and projection. The stereotypical Asian nose is rounded and bulbous. We question the meaning and significance of NTA

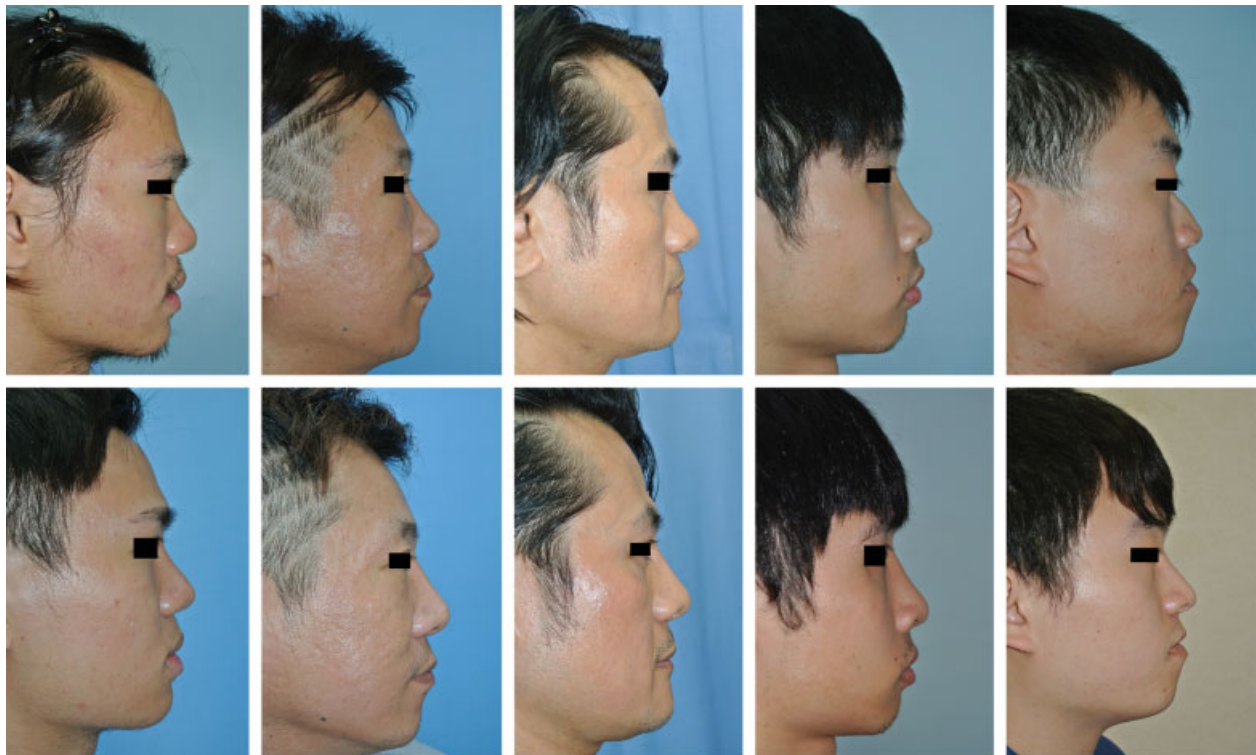


Fig. 8 Preoperative (*above*) and postoperative (*below*) images of men who benefited from M-TAG rhinoplasty and dorsal augmentation. Sharpening of the nasal tip, as reflected by a decrease in the RI, may confer a masculinizing effect in men.

and rotation parameters of an object that is not so much a point as it is a gentle curve. Although many noses may appear over-rotated, this may reflect roundness more so than rotation. We suggest that by elongating the dorsum, the roundness is reduced and the tip appears less rotated and more projected. In other words, increasing the dorsal length and projection of a bulbous tip amounts to RI reduction and enhanced appearance.

There was a trend toward increased ACWI and nostril axis angle when patients were followed up for more than 6 months. Although this did not reach statistical significance, it suggests that the nasal base may splay with time. Possible causes include soft-tissue contracture over a fixed rigid framework or loss of support resulting from scroll area dissection. This finding is probably unrelated to the lack of a columellar strut, as tip projection and columellar length did not change after 6 months.

The M-TAG technique does not rely on the anterior nasal spine for support; this distinguishes it from other methods. However, this requires caudal septal alignment and stability. Although ESG strength draws heavily from dorsal structures, force transmission through the caudal septum cannot be dismissed. In our experience, preservation of a 10-mm L-strut is adequate. If the preserved strut is severely deviated, septal alignment should be corrected or another strategy pursued prior to attempting M-TAG rhinoplasty.

Major limitations of this study include lack of comparative measures, and nearly homogenous Taiwanese patient population that may or may not accurately reflect people of northern and southern Asian extractions. The greatest limitation is the short follow-up time. We confronted this considerable shortcoming by comparing change in groups with shorter and longer follow-up and we observed significant differences. Similarly, Kim et al reported durable photogrammetric change with a comparable SEG technique in Koreans that did not change in patients followed up for 11 months, 12 to 23 months, and >24 months.²⁵ We acknowledge that longer follow-up would enhance this study. Conchal cartilage used as cap or shield graft may have influenced tip projection and rotation. Because these grafts were generally 1 mm thick or less, we imagine the effect was minimal, but it is difficult to exclude this bias.

Conclusion

Autologous Asian rhinoplasty is challenging because of its augmentative nature and intrinsic deficiencies of donor tissue. We modify important preexisting methods to address these challenges. Significant tip changes were achieved without alloplastic material and are expected to withstand the test of time. Decrease in tip roundness may better reflect patient goals and postoperative changes than conventional parameters established in the Western literature. An emphasis on economized resource allocation, predominant dorsal load sharing, and relative independence from caudal support distinguish this safe, feasible, and customizable method.

Conflict of Interest

The authors have no financial or personal conflicts of interest to disclose.

Funding

The authors deny external funding support relevant to this or any study.

Level of Evidence

IV (Therapeutic).

References

- Lam SM. Asian rhinoplasty. *Semin Plast Surg* 2009;23(3):215–222
- Byrd HS, Andochick S, Copit S, Walton KG. Septal extension grafts: a method of controlling tip projection shape. *Plast Reconstr Surg* 1997;100(4):999–1010
- Chang YL. Correction of difficult short nose by modified caudal septal advancement in Asian patients. *Aesthet Surg J* 2010;30(2):166–175
- Dhong ES, Kim YJ, Suh MK. L-shaped columellar strut in East Asian nasal tip plasty. *Arch Plast Surg* 2013;40(5):616–620
- Han K, Jeong JW, Kim JH, et al. Complete septal extension grafts using porous high-density polyethylene sheets for the westernization of the Asian nose. *Plast Reconstr Surg* 2012;130(1):106e–115e
- Huang J, Liu Y. A modified technique of septal extension using a septal cartilage graft for short-nose rhinoplasty in Asians. *Aesthetic Plast Surg* 2012;36(5):1028–1038
- Jeong JY. Obtaining maximal stability with a septal extension technique in East Asian rhinoplasty. *Arch Plast Surg* 2014;41(1):19–28
- Kang JG, Ryu J. Nasal tip surgery using a modified septal extension graft by means of extended marginal incision. *Plast Reconstr Surg* 2009;123(1):343–352
- Kim JH, Song JW, Park SW, Oh WS, Lee JH. Effective septal extension graft for Asian rhinoplasty. *Arch Plast Surg* 2014;41(1):3–11
- Lin J, Chen X, Wang X, et al. A modified septal extension graft for the Asian nasal tip. *JAMA Facial Plast Surg* 2013;15(5):362–368
- Zhou J, Huang X, Zheng D, Li H, Herrler T, Li Q. Oriental nose elongation using an L-shaped polyethylene sheet implant for combined septal spreading and extension. *Aesthetic Plast Surg* 2014;38(2):295–302
- Suh MK, Ahn ES, Kim HR, Dhong ES. A 2-year follow-up of irradiated homologous costal cartilage used as a septal extension graft for the correction of contracted nose in Asians. *Ann Plast Surg* 2013;71(1):45–49
- Kim YH, Kim BJ, Jang TY. Use of porous high-density polyethylene (Medpor) for spreader or extended septal graft in rhinoplasty: aesthetics, functional outcomes, and long-term complications. *Ann Plast Surg* 2011;67(5):464–468
- Gruber RP. Surgical correction of the short nose. *Aesthetic Plast Surg* 2002;26(Suppl 1):S6
- Toriumi DM, Pero CD. Asian rhinoplasty. *Clin Plast Surg* 2010;37(2):335–352
- Guyuron B, Varghai A. Lengthening the nose with a tongue-and-groove technique. *Plast Reconstr Surg* 2003;111(4):1533–1539, discussion 1540–1541
- Katira K, Guyuron B. Contemporary techniques for effective nasal lengthening. *Facial Plast Surg Clin North Am* 2015;23(1):81–91
- Han K, Kwon HJ, Choi TH, Kim JH, Son D. Comparison of anthropometry with photogrammetry based on a standardized clinical

- photographic technique using a cephalostat and chair. *J Cranio-maxillofac Surg* 2010;38(2):96–107
- 19 Joseph J. Nasenplastik und sonstige Gesichtsplastik nebst einem Anhang ueber. Mammoplastik. Leipzig: Kabitsch; 1931
- 20 Won TB, Jin HR. Nuances with the Asian tip. *Facial Plast Surg* 2012; 28(2):187–193
- 21 Kwon TK. Complications found in Asian tip surgery. *Facial Plast Surg* 2012;28(2):238–242
- 22 Choi JY, Kang IG, Javidnia H, Sykes JM. Complications of septal extension grafts in Asian patients. *JAMA Facial Plast Surg* 2014; 16(3):169–175
- 23 Caughlin BP, Been MJ, Rashaan AR, Toriumi DM. The effect of polydioxanone absorbable plates in septorhinoplasty for stabilizing caudal septal extension grafts. *JAMA Facial Plast Surg* 2015; 17(2):120–125
- 24 Farkas LG, Kolar JC, Munro IR. Geography of the nose: a morphometric study. *Aesthetic Plast Surg* 1986;10(4): 191–223
- 25 Kim JS, Han KH, Choi TH, et al. Correction of the nasal tip and columella in Koreans by a complete septal extension graft using an extensive harvesting technique. *J Plast Reconstr Aesthet Surg* 2007;60(2):163–170